

**PATHOGENICITY OF *HENNEGUYA PSOROSPERMICA*
(PHYLUM MYXOZOA) ON FRESHWATER SPECIES OF
FISH ORIGINATING FROM THE DANUBIAN DELTA**

**PATOGENITATEA LUI *HENNEGUYA PSOROSPERMICA*
(PHYLUM MYXOZOA) ASUPRA SPECIILOR DE PEȘTI
DULCICOLI PROVENIȚI DIN DELTA DUNĂRII**

HANGAN M.*, URDEȘ LAURA**,
DIACONESCU CRISTIANA**, VASILE P.***,

*Faculty of Biotechnologies, Bucharest, Romania

**Faculty of Animal Sciences, Bucharest, Romania

***S. C. Piscicola Tour S.R.L., Jurilovca, jud. Tulcea

*The aim of this scientific work consisted in establishing the specific ethiology of gills infection, which has been found on the occasion of regular clinic and anatomo-pathological examinations, in some freshwater species of fish originating from the Danubian Delta area. Following these examinations, there has been pointed out the macroscopical lesions of gills together with the presence and morphology of parasitic cysts. The microscopic examination of the cysts resulted in diagnosing the specific pathological agent, which was the metazoan *Henneguya psorospermica*. These aspects and more are being presented in this paper.*

Key words: pikeperch (*Sander lucioperca*), pike (*Esox lucius*), *Henneguya psorospermica*, pathogenicity on fish

Introduction

Henneguya sp. is one of the highly specialized metazoan parasites of aquatic hosts. Interest in the group of Myxozoans has intensified along with the aquaculture, as many species are known to cause disease outbreaks in farmed fish species and wild fish stocks, in both freshwater and marine environment. Nowadays, the development of specific diagnostic methods has facilitated studies of pathogenesis and has provided fundamental advances in the taxonomy and biology of Myxozoa. Current research continues to be focused on phylogeny, pathogenicity and the occurrence of disease outbreaks.

When *Henneguya sp.* is on the bases of one or more of outbreaks, the frequency of mortality in the fish population is low. In such cases, the mortality is registered only when the parasite is situated on organs that have a strategic importance, like heart and gills (5). Yet, infection with the myxozoan *Kudoa spp.* within the musculature reduces severely the flesh quality and cause

myoliquefaction (1). *Henneguya*'s most frequent locations in freshwater fish are on gills, skin and fins (4).

According to the speciality literature (2-5), there are 150 species of *Henneguya* cited all over the world, from which 31 are known to exist only in the South of America (2). Some species, as *H. leporinicola*, *H. curvata*, *H. iheringi*, *H. striolata*, *H. chrysiichthyi*, *H. salmonicola*, *H. dogieli*, *H. gigantea*, *H. psorospermica*, *H. zshokkei* and *H. creplini.*, have been found also in Romania, in some freshwater groups of fish, having been brought, possibly, through the movement of either live or dead fish, destined for consumption (1).

Materials and Methods

The study was carried out on a total of 75 freshwater fish, split into two major groups. The first group consisted in 25 pikes that were gathered on October 2005 from the Isac Lake (Murighiol collecting point). The second group consisted in 50 pikeperch that was gathered from Sulina branch (Gorgova collecting point). The second group was divided in two half, according to the time of gathering, as follows: a half was gathered on March 2006, while the other half, on March 2007. All individuals of pikeperch had an average of 40-60 cm (body lengths) and pikes had on average 40-70 cm (body lengths). In order to diagnose the parasite on the two species studied, we used parasitological, clinical and anatomo-pathological examinations. The parasitological examination consisted in fresh preparations of cysts examined in light microscopy. Some preparations were colored by the green malachite technique.

Results and Discussions

Folowing the anatomo-clinic examinations, it has been noticed a large number of parasitic cysts varying in size, morfology and location between the two studied species of fish (figs. 5, 6).

In *Sander lucioperca*, cysts found on gills were white, fusiforms, of roughly 3 cm length, and were located on one or more gill filaments (figs. 5, 7).

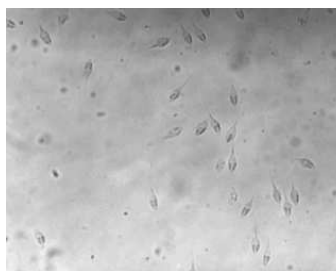


Fig. 1 – *H. psorospermica* spores in pike (M.O. 40 x)

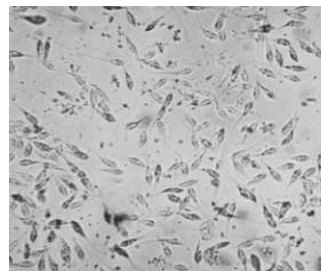


Fig. 2 - *H. psorospermica* spores in pikeperch (M.O. 40 x)

In *Esox lucius*, the cysts were white, of elliptic shape and had 3-5 cm length (fig. 6). In the majority of the cases, the cysts were found parasiting one or both gills.

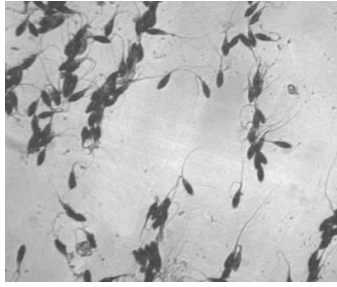
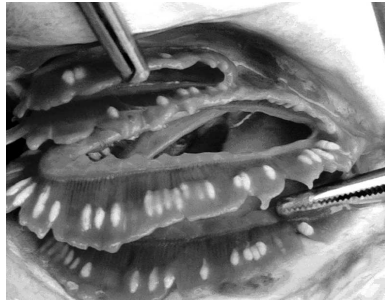


Fig. 3 - *H. psorospermica* spores in pikeperch (green malachite, 40 x)

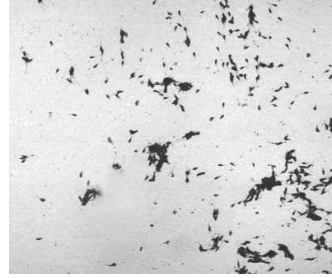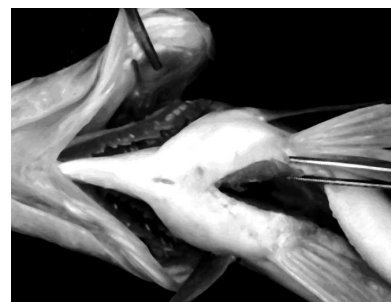


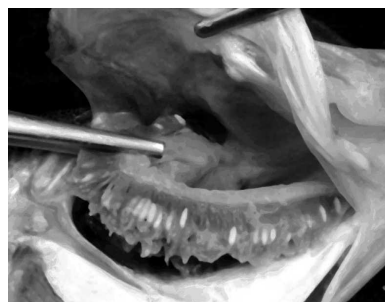Fig. 4 - *H. psorospermica* spores in pikeperch (green malachite, 10 x)

From the lesional point of view, in both species, the gills showed congestion and necrosis and into the opercular cavity an extremely consistent mass of branchial mucus was present (figs. 6, 7). In some cases, it has been observed in both species signs of anaemia and hypoxia.



Figs. 5, 6 – Differences in size, shape and location of *H. psorospermica* cysts in: 5-pikeperch; 6-pike



Figs. 7, 8 – Congestion and necrosis in hennequiosis in pikeperch (7) and pike (8)

Conclusions

1. Following the clinic and anatomo-pathological examinations on this study, it has resulted:

1.1. Clinic signs of henneguyasis were generally unspecific. Only in chronic infections and in the fish that showed a high level of infection, the signs of anaemia and respiratory disturbance could be observed;

1.2. Cyst's size, morphology and location on gills have varied between the two species of the studied fish;

1.3. From the lesional point of view, the gills showed congestion, necrosis and a whitish, adherent and consistent mucus.

2. Following the microscopic examination resulted that the spores which were isolated from the cysts were spores of *H. psorospermica*.

Bibliography

1. **Bartholomew, J.L., Reno, P.W.** (2002) – *The history and dissemination of whirling disease*. In: Reviews and Current topics. Symposium 29, American Fisheries Society, Maryland, 247

2. **Bianca, B., Edson, A.A., Sarah, A., Nelson, S.C.** (2003) – *Henneguya curvata* sp. N. (*Myxosporea: Myxobolidae*) parasiting the gills of *Serrasalmus spilopleura* (*Characidae: Serrasalminae*), a South American freshwater fish, *Folia Parasitologica* 50: 151-153, Brasil, Campinas

3. **Bogatu, D.** (1968) – *Contribuțiuni la studiul parazitofaunei peștilor din Dunăre – zona viitorului lac de acumulare de la Porțile de Fier*, Comunicări seria Hidrobiologie, 3-14, Ed. Acad. R.S.R., Craiova

4. **Bogatu, D., Gabriela Munteanu, Lazu, D.** (1979) – *Cercetări privind bolile parazitare la unele specii de pești din Oceanul Atlantic*, *Lucrările Ses. Științ. Univ.*, vol. IV, 321-328, Galați

5. **Gabriela Munteanu, Bogatu, D.** (2003) – *Tratat de ihtiopatologie*, Ed. Excelsior art, Timișoara